

Ultrasound-guided Foam Sclerotherapy Combined with Sapheno-femoral Ligation Compared to Surgical Treatment of Varicose Veins: Early Results of a Randomised Controlled Trial

D.G. Bountouroglou, M. Azzam, S.K. Kakkos, M. Pathmarajah, P. Young and G. Geroulakos*

Josef Pflug Vascular Laboratory and the Vascular Unit, Ealing Hospital, Department of Vascular Surgery, Imperial College, London, UK

Aim. This study is a prospective randomised controlled trial comparing sapheno-femoral ligation, great saphenous stripping and multiple avulsions with sapheno-femoral ligation and ultrasound guided foam sclerotherapy to the saphenous vein. Primary end points were patient recovery period and quality of life and secondary end points frequency of complications on the two arms of the trial and the cost of the treatment.

Material and method. Sixty patients with primary varicose veins due to GSV incompetence and suitable for day case surgery were randomly allocated to undergo ultrasound-guided sclerotherapy with sapheno-femoral ligation under local anaesthesia (n=30) or sapheno-femoral ligation, stripping and multiple avulsions under general anaesthesia (n=30). The study protocol included history, physical examination, assignment of CEAP class and assessment venous clinical severity score (VCSS), completion of the aberdeen vein questionnaire (AVQ) and colour duplex ultrasound.

Results. All treatments were completed as intended. Median time to return to normal activities was significantly reduced in the foam sclerotherapy group (2 days) compared to the surgical group (8 days) ($p < 0.001$, Mann–Whitney).

AVQ score was also significantly reduced at 3 months by 46% in the sclerotherapy group, and by 40% in the conventional surgery group ($p < 0.001$, Wilcoxon).

The time taken to complete treatment was shorter in the foam sclerotherapy plus SFJ ligation group: 45 vs. 85 min ($p < 0.001$, Mann–Whitney).

The overall cost of the procedure in the sclerotherapy group (£672.97) was significantly less compared to conventional surgery (£1120.64).

At 3 weeks, there was no statistical difference in the complication rate between the two groups. At 3 months, median CEAP class dropped from four pre-operatively to one following treatment in both groups and the median VCSS score dropped from five to one in group one and from seven to three in group two ($p < 0.001$, Wilcoxon test). In group one four patients (13%) had a recanalised vein which needed further sessions of foam sclerotherapy, resulting in a short-term closure rate of 87%.

Conclusion. Ultrasound guided sclerotherapy combined with sapheno-femoral ligation was less expensive, involved a shorter treatment time and resulted in more rapid recovery compared to sapheno-femoral ligation, saphenous stripping and phlebectomies.

Keywords: Randomised trial; Ultrasound-guided foam sclerotherapy varicose veins; Quality of life; Varicose vein surgery.

Introduction

Ligation of the saphenofemoral junction (SFJ), stripping of the great saphenous vein (GSV) and multiple phlebectomies is considered the standard treatment for varicose veins. This achieves rapid relief of

symptoms and has an acceptable long-term recurrence rate.^{1,2} Any alternative technique must have the same or better outcome with fewer complications or reduced cost. Stripping of the GSV is not used at present in some centres on the basis that selective ligation of incompetent veins is as effective as stripping and results in less morbidity by decreasing the incidence of thigh haematomas and post-operative pain. However, it has been reported that the residual incompetent GSV results in a higher recurrence rate for varices.³ Others have proposed ligation of major sites

*Corresponding author. Dr George Geroulakos, FRCS, PhD, Consultant-Senior Lecturer, Department of Vascular Surgery, Faculty of Medicine, Imperial College, Charing Cross Hospital, Fulham Palace Road, London W6 8RF, UK.
E-mail address: g.geroulakos@imperial.ac.uk

of venous incompetence such as the SFJ followed by sclerotherapy of the GSV.³ Foam sclerotherapy under ultrasound control is a relatively new technique that appears to be safer and more effective than liquid sclerotherapy.⁴⁻⁷

The present study was designed as a prospective randomised comparison of conventional GSV stripping and SFJ ligation under general anaesthesia with ultrasound guided foam sclerotherapy and SFJ ligation under local anaesthetic. The primary outcome measures were time for post-operative recovery and return to work and quality of life (QOL) outcomes and the secondary outcome measures frequency of complications and cost of treatment.

Materials and Methods

The study protocol was approved by the Hospital Ethics Committee. Patients with symptomatic primary varicose veins (VV) due to GSV incompetence attending the vascular outpatient clinic of Ealing Hospital were invited to participate in this study. Patients who gave informed written consent were included. Sixty patients, 32 female and 28 male with a median age of 43 years (range 20–72 years), meeting the inclusion and exclusion criteria listed in Table 1 were enrolled and randomised between July 2003 until February 2004. The randomisation was done with sealed envelopes prepared by STD Pharmaceuticals Ltd the study sponsors. After consent had been obtained, the envelope assigned to the patient was opened allocating him/her to one of the two groups: SFJ ligation, GSV stripping and phlebectomies (surgery group) or SFJ ligation under local anaesthetic and foam sclerotherapy to the GSV (foam sclerotherapy group). Thirty patients were allocated to the foam sclerotherapy group and 30 to the surgery group. Only

Table 1. Inclusion and exclusion criteria

Inclusion criteria	
Patients with primary symptomatic varicosities involving the LSV system	
No previous treatment for varicose veins	
Suitability for day-case surgery	
Exclusion criteria	
Patients with primary varicosities involving both the LSV and SSV	
Patients with previous surgery for varicose veins	
Patients previously treated with sclerotherapy for varicosities	
Previous DVT	
Risk factors for DVT (apart from varicose veins)	
Coagulopathy	
Peripheral vascular disease	
Known allergy to local anaesthetic or sclerosing agents	
Previous iatrogenic allergic reaction	
Malignancy	
Pregnancy	

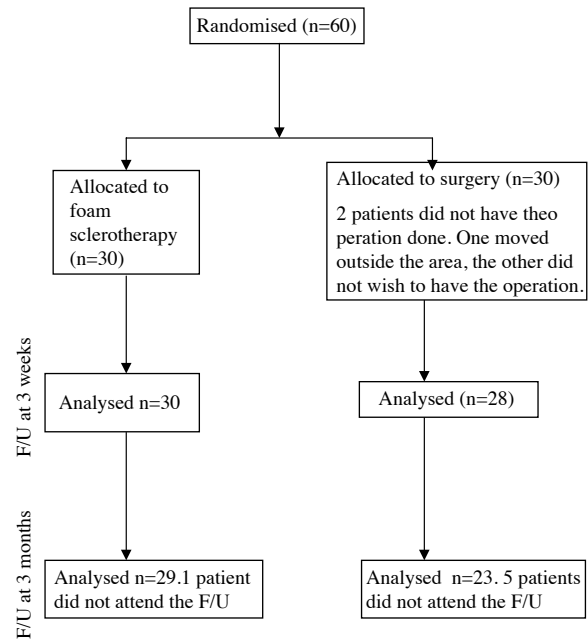


Fig. 1. CONSORT diagram showing flow of patients through the study.

one leg per patient was included in the study in patients with bilateral varicose veins the most severely affected limb was randomised for the purposes of this investigation. The flow of patients in this study is shown in Fig. 1.

Investigation protocol

The investigation protocol entailed: history; physical examination and allocation to the appropriate CEAP^{8,9} clinical stage and venous clinical severity score (VCSS) classification.^{10,23} Lower limb venous duplex ultrasound examination was undertaken and patients completed the Aberdeen Vein Questionnaire (AVVQ). This was employed to assess the impact of treatment on the quality of life.¹¹

On clinical examination all patients had normal pulses in the lower limb and there was no clinical evidence of peripheral arterial disease. The examination also included screening the superficial venous system of the lower limb with continuous-wave Doppler ultrasound. Limbs were classified according to the CEAP system,⁸ and quantification of clinical severity was performed using the VCSS introduced by Rutherford *et al.*¹⁰

Lower limb venous duplex scanning was performed by the same operator (MA), using an Acuson (Aspen Advanced, Acuson Corporation, USA) fitted with a 4–8 MHz linear array transducer. The examination was performed with the patient standing. Reflux

was defined as reverse flow longer than 0.5 s following a manual compression-release manoeuvre.

Operative procedure

All patients treated in this study were managed in our day surgery unit with the aim of discharging them from hospital on the day of treatment.

In the surgery group, the operation was performed under general anaesthesia. Following SFJ ligation, GSV stripping was performed using an inversion technique from proximal to distal using a plastic stripper. The GSV was stripped from the SFJ to just below the knee. Varicosities were treated by phlebectomy using Müller's hooks, through multiple small incisions. After wound closure compression bandages were applied, which were changed for a class 1 (Germany) elastic stocking (MEDIVEN PLUS™, Medi, Bayreuth, weihermuller, Beyreuyh, Germany) (18–21 mmHg) prior to patient discharge from the day ward, and maintained for 3 weeks. All patients were instructed to walk for 1.5–2 mile on a daily basis.

The duration of the treatment was recorded in the two groups. The operating time in the surgery group incorporated the anaesthetic preparation of the patient. The operating time in the foam sclerotherapy group incorporated the sclerotherapy session.

In the foam sclerotherapy group, the procedure was performed under local anaesthesia, which consisted of 10 ml of bupivacaine 0.5%, prior to the groin incision and lignocaine 1% with adrenaline (1:100.000) as needed during the procedure. SFJ ligation was performed in the same way as in the surgery group. Post-operatively, the patient was transferred to the ultrasound suite where foam injection sclerotherapy with 6 ml of sclerosing foam under ultrasound control was performed. The sclerosing foam was prepared using the Tessari method,¹² with two disposable 5 ml syringes and a three-way stop-cock. One part of 3% STD (Fibrovein™, STD Pharmaceutical Products Ltd, Hereford, UK) and four parts of air were used to produce the sclerosing foam. A suitable varicose vein, connecting with the GSV trunk, preferably below the knee, was selected, marked with the aid of ultrasound and with the patient in supine position, was subsequently cannulated with a 21-gauge butterfly. The limb was then elevated to 45° and the sclerosing foam injected. Directional control of sclerosant flow was accomplished by application of pressure with the ultrasound transducer along the course of the treated vein(s). Any perforating veins were protected by applying digital pressure to prevent foam entering

the deep venous system. The aim was first to treat and obliterate the segment of the GSV that otherwise would have been stripped.

On completion, the deep venous system was scanned to identify any foam leakage. Short stretch bandages (CEB IDEAL BP elastic, Karl Otto Braun, Germany, 7.5 and 10 cm wide) with latex foam rubber pads (STD Pharmaceutical Products Ltd, Hereford, UK) were applied in the treated area and a class I (Germany, 18–21 mmHg) thigh-high stocking with a waist attachment (MEDIVEN PLUS™, Medi, Bayreuth, Germany) was worn. Patients were instructed to wear the stocking continuously for 2 weeks. During the third week patients were allowed to wear the stocking in the daytime only. Patients were advised to walk for 1.5–2 mile daily, starting on the day of the operation. The authors admit that there is no scientific evidence to support this regime but have found it useful advice to offer in order to facilitate recovery of their patients to normal activity following this type of surgery.

Follow-up

All patients were reviewed and examined 3 weeks and 3 months post-operatively. The follow-up evaluation at 3 weeks included history, physical examination and colour duplex venous ultrasound. History and physical examination were aimed at detecting any complication. The colour duplex examination stratified the GSV system as fully obliterated (1), partially obliterated with (2a) or without (2b) reflux, or not obliterated (3). In addition, the presence of DVT was sought. The common femoral vein, the femoral vein, the popliteal vein, the posterior tibial veins, the peroneal veins, the soleal veins and the medial and lateral gastrocnemius vein were investigated by colour duplex ultrasonography using a standardised technique.⁸

All patients with residual varicose veins in both groups received additional foam (foam sclerotherapy group) or liquid (surgery group) sclerotherapy treatment as outpatients. The follow-up evaluation at 3 months included classification using the CEAP and VCSS systems and the completion of the AVVQ.

Statistical analysis

Non-parametric tests, Wilcoxon signed ranks test and Mann–Whitney test, were used for statistical analysis of paired data (i.e. score changes overtime) and unpaired data (i.e. differences between groups), respectively. Calculation was performed with the statistical package SPSS for Windows (version 11.5),

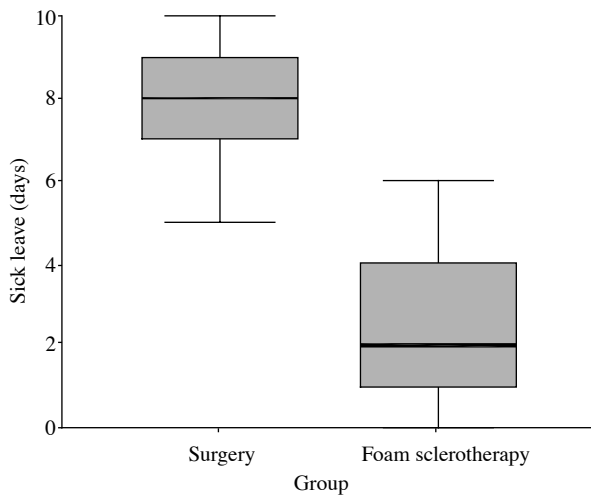


Fig. 2. Length of time until return to normal physical activity ($p < 0.001$, Mann–Whitney test). The box and whisker plot shows the median, inter-quartile range and maximum and minimum values.

Chicago, IL, USA; Figs. 2 and 3 were prepared using the statistical package STATISTICA (version 7). The descriptors used in these figures are the median, interquartile range and maximum and minimum values. Before the authors started this study there was no detailed information on the main outcome measures that we wished to investigate. The patients reported here represent our initial experience of this technique. We, therefore, had no reliable data on which to base power calculations in order to establish an appropriate sample size. The number of patients included was determined by the maximum that was

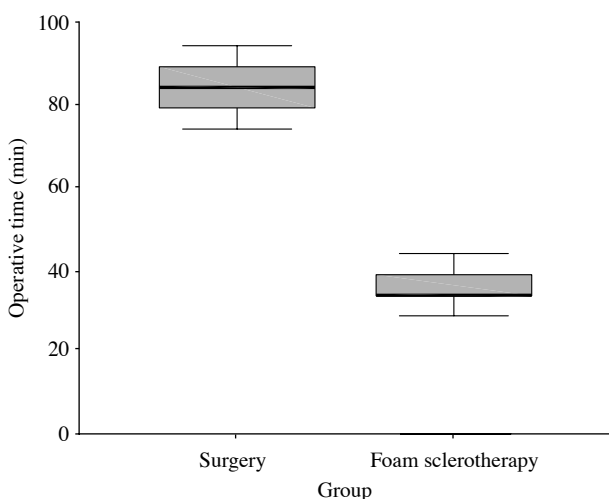


Fig. 3. Length of time of the operative procedure ($p < 0.001$, Mann–Whitney test). The box and whisker plot shows the median, inter-quartile range and maximum and minimum values.

feasible taking into account the resources available to the authors.

Results

All treatments were completed as intended and no procedure was abandoned due to technical difficulty. Two patients in the conventional surgery group have not yet had their operation and were not included in the final analysis. One of them changed his mind and did not want to have the operation and the other has moved to a different area. Two patients in the foam sclerotherapy group received the same treatment to the other leg at their request, but these added procedures were not part of the trial and were not included in the final data analysis. The two patient groups had comparable demographics, CEAP classification, and clinical severity of venous disease (VCSS) as shown in Table 2.

The time until return to work or back to normal activity ranged from 0 to 6 days (median 2) in the foam sclerotherapy group, and from 5 to 20 days (median 8) in the surgery group (Fig. 2). The difference was statistically significant ($p < 0.001$, Mann–Whitney).

Quality of life analysis with the AVVQ showed that median scoring decreased from 15.4 to 9.3 (46%) in the foam sclerotherapy group and from 26.1 to 14.1 (40%) in the surgical group after 3 months ($p < 0.001$, Wilcoxon).

Treatment time for the two techniques is shown in Fig. 3. The length of the procedure ranged from 45–60 min (median 45) in the foam sclerotherapy group, and from 70–95 min (median 85) in the surgery group ($p < 0.001$, Mann–Whitney). The procedural cost of the two techniques is analysed in Table 3.

The total cost of the procedure in group 1 was £672.97 (GBP) as compared to £1120.64 (GBP) in group 2.

Table 2. Demographics, CEAP and VCSS before treatment (significance testing: Mann–Whitney U-test)

	Foam sclerotherapy group	Surgical group	<i>p</i> value
Age	21–72 (median 43)	20–76 (median 43)	NS
Female gender	14 (47%)	18 (60%)	NS
CEAP clinical class			
2	11 (37%)	8 (27%)	NS
3	8 (27%)	14 (47%)	NS
4	7 (23%)	6 (20%)	NS
5	3 (10%)	1 (3%)	NS
6	1 (3%)	1 (3%)	NS
VCSS	2–13 (median 7)	2–16 (median 5)	NS

Ultrasound-guided Foam Sclerotherapy Combined with Sapheno-femoral Ligation

Table 3. Early post-operative complications

Complications	Foam sclerotherapy group	Surgery group
Groin infection	2	2
Skin pigmentation	2	1 (skin ulcer)
Sup. thrombophlebitis	3	–
Allergy	–	–
DVT	–	–
Saph. nerve injury	–	2
Other	–	2 (haematoma, retention)

Post-operative follow-up

Complications arising from the procedure were infrequent in both groups (Table 4). Two groin infections occurred in each group and were treated successfully with antibiotics. There were two cases of skin pigmentation and one case of superficial thrombophlebitis in the sclerotherapy group. One groin haematoma, which needed surgical evacuation, and an immediate post-operative urinary retention, occurred in the surgery group. The latter patient was kept overnight in hospital. There were no significant complications, such as deep vein thrombosis (DVT), pulmonary embolism, peripheral nerve injury, skin necroses, or allergic reaction to the sclerosing drug.

Four patients (13.3%) in the foam group needed a second session of sclerotherapy for full obliteration of the GSV system. This resulted in a mean of 1.13

sclerotherapy sessions per patient to completely occlude the GSV.

In the stripping group two patients (7%) needed a further sclerotherapy session for full obliteration of their residual veins.

Fifty-one patients (28 patients in group one and 23 patients in group 2) have so far been followed up at 3 months.

Five patients in the foam group (17%) had developed resolving skin pigmentation and three (10%) had had an episode of self-limited superficial thrombophlebitis. In the conventional surgery group two patients (9%) complained of symptoms suggesting saphenous nerve injury, and one patient (4%) developed a skin ulcer following liquid injection sclerotherapy for her residual varicose veins.

The median CEAP class dropped from four pre-operatively to one following treatment in both groups and the median VCSS score dropped from five to one in group one and from seven to three in group two ($p < 0.001$, Wilcoxon test, Table 5). In both groups the changes of the VCSS score and CEAP class pre- and post-operatively were comparable.

In the foam sclerotherapy four patients (13%) had recanalised a vein (2b or 3) needing further sessions of foam sclerotherapy, resulting in a short-term closure rate of 87%. In group two there were two cases of incomplete stripping (accessory LSV) resulting in a short-term obliteration of 93%. Table 6 summarises the post-operative ultrasound scan assessment of the GSV system.

Table 4. Expenditure of the procedure in the two groups

Surgery	Comment	Conventional	Foam injection sclerotherapy
Surgeon	@ £1.17 per min	£93.60	£40.95
Assistant	@ £0.49 per min	£39.20	£17.15
Anaesthetist	@ £1.17 per min	£93.60	£0.00
Nursing	@ £0.68 per min	£54.40	£23.80
Anaesthetic	Standard v local (ignoring gas/vapor and monitoring cost)	£8.36	£2.84
Anaes assistant	@ £0.25 per min	£20.00	£0.00
Consumables	Stripper v STS	£8.55	£4.69
	Antiembolism stockings	£7.00	£17.50
Sterile supplies		£80.56	£80.56
	Subtotal A	£405.27	£187.49
POST OP			
Theatre recovery	@ £100 per h	£83.33	£40.00
Ward time	@ £100 per h	£491.67	£258.33
Lost time before return			
Normal activities		7 days	2 days
Ultrasound	15 min scan. This cost can be eliminated by using handheld devices in theatre, adding 10 min to the theatre time, or £23.40	£0.00	£50.00
	Medical attendance		£7.95
Capital and overhead		£ 140.37	£71.70
	Subtotal B	£715.37	£485.48
	Grand total	£1,120.64	£672.97

Table 5. Effect of procedure on CEAP and VCSS stratification

	Foam sclerotherapy		Surgery	
	Pre	Post	Pre	Post
CEAP				
Median (range)	4 (2–6)	1 (0–5)	4 (2–6)	1 (0–5)
VCSS				
Median (range)	5 (2–13)	1 (0–5)	7 (2–16)	3 (0–4)

($p < 0.001$, Wilcoxon)

Discussion

Rutgers and Kitslaar,³ and Jones *et al.*¹³ have shown that SFJ ligation with stripping of the great saphenous vein is associated with lower recurrence rate of reflux and VVs than SFJ ligation alone. SFJ ligation was associated with increased morbidity consisting of post-operative pain and bruising. In the present study the inversion technique for stripping of the GSV was used.

In a randomised trial,¹⁴ comparing the GSV stripping to liquid sclerotherapy given without ultrasound guidance five hundred patients were followed up for up to 6 years. At 1 year sclerotherapy was more effective with a very high cure rate (95%) but this began to fail at 2 years (67%). The cure rate decreased markedly during the fourth (17%), fifth (10%) and sixth (5%) years after treatment. At 1 year surgery showed a lower success rate (60%), but this did not fall rapidly with time. Cavezzi *et al.*¹⁵ followed up 177 limbs for a mean time of 138 days and observed a 33% recurrence rate after ultrasound guided foam sclerotherapy for varicose veins. Cabrera *et al.*¹⁶ treated five hundred limbs with ultrasound guided foam sclerotherapy and report an 81% obliteration rate after 3 years follow-up.

Ultrasound guided foam sclerotherapy appears to be superior to liquid sclerotherapy^{4–7} (or Orbach's froth). A randomised study of 25 patients treated with liquid sclerotherapy or saline injections identified 23.2% of recanalisation rate after 3 months in the

Table 6. Ultrasound follow-up investigation (LSV system.1, full obliteration; 2a, partial obliteration without reflux; 2b, partial obliteration with reflux; 3, no obliteration)

	u/s grade	3 weeks		3 months	
		Legs	%	Legs	%
Foam sclerotherapy group	1	25	83	23	79
	2a	1	3.3	2	7
	2b	4	13.3	4	14
	3	0	0	0	0
Surgery group	1	25	89.3	18	78.3
	2a	1	3.6	1	4.3
	2b	2	7	4	17.4
	3	0	0	0	0

sclerotherapy group.¹⁷ Hamel-Desmos *et al.* compared early results between foam and liquid sclerotherapy.²⁰ Eighty-eight limbs were randomised and the 3 weeks follow-up identified 84% GSV obliteration in the foam group and only 40% in the liquid sclerotherapy group.

The high incidence of recurrence is largely the result of recanalisation of the GSV following sclerotherapy. Therefore, in this study we combined high ligation with sclerotherapy, a treatment that theoretically would have a lower recurrence rate than sclerotherapy alone. Our recanalisation rate of the GSV was lower than the one reported by Cavezzi *et al.* who used a similar technique without ligating the SFJ. We acknowledge that the technique used by Cavezzi differs from ours. Another advantage of ligating the SFJ is that the tributaries are also ligated during this operation. These remain patent following sclerotherapy and may act as a source of recurrence.^{2,18}

A theoretical long-term disadvantage of the ligation of the SFJ is that this procedure could induce neo-vascularisation of the saphenofemoral junction, which results in varicose vein recurrence. Neo-vascularisation is a common cause of recurrent varicose veins. A randomised study reported in a 2 year follow-up a 35% of recurrence after high ligation with (25%) or without (43%) stripping. 52% of the recurrences was found to be due to neo-vascularisation.¹⁹ In our study, this problem will need to be quantified and addressed in the long-term follow-up of our patients.

The authors are aware that retrograde injection of the saphenous trunk with liquid sclerosants at the time of surgery has been reported. We opted to use foam injections and monitor the extent of spread of the foam during treatment. Since, ultrasonography was not available to us in the operating theatre we decided to treat patients in a separate session where we could direct foam to the saphenous trunk and as many varices as possible. We found it sufficient to inject a tributary of the saphenous trunk in this series. We acknowledge that in many of the published series on this subject the sclerosant foam has been delivered directly into the saphenous trunk. We considered that in our patients where the sapheno-femoral junction had been ligated surgically the increased complexity and possible risks of injection of the saphenous trunk could be avoided. Our results have so far confirmed that this strategy was effective. Prior ligation of the SFJ may also increase the safety of this procedure by limiting the spread of sclerosant foam to the femoral vein.

This prospective randomised trial provides direct comparison of the early post-operative course after conventional treatment of primary varicose veins with SFJ, stripping and avulsions, and ultrasound-guided

foam sclerotherapy and SFJ ligation under local anaesthetic. The operative time of the two treatments in this study proved to have a significant reduction in favour of the foam group. In this study the sclerotherapy session was carried out in the ultrasound suite after the operation. The mean time of the procedure was 15 min. If the sclerotherapy procedure was done in theatres then the operative time would have been even less.

We found that patients in the foam sclerotherapy group returned to work earlier than those in the surgery group (median 2 *vs.* 8 days). Recovery was quicker, early cosmesis was better with fewer incisions in patients treated with foam.

Quality of life analysis showed that the foam and high ligation technique achieved reduced discomfort from varices and cosmetic improvement comparable to that achieved in the conventional surgery group.

The cost of the procedure was found to be almost half (£673 *vs.* £1121) for patients treated with foam sclerotherapy and high ligation. The cost of the procedure does not take into account socio-economic benefits and in particular the much earlier return to professional activities among those treated with foam sclerotherapy. This has important implications in the era of day case surgery, because it could result in more patients being treated during a day list, thus reducing the long waiting lists in varicose vein surgery.

Complications were similar in both groups, being more annoying than serious. The groin infection rate in each group (6.6%) although higher than the figures described in textbooks (<5% in clean operations), were lower than the reports of a prospective study which showed a surprisingly high overall infection rate of 13.5% in 126 patients after vein stripping.²¹

The rate of the GSV system obliteration was equal in the two study groups, and in accordance with other studies^{6,22} stratification of patients in the CEAP class and VCSS showed a significant decrease in scoring in both groups.

The ideal treatment for varicose veins should be relatively non-invasive, repeatable if necessary; relatively safe and free of significant complications; effective in eliminating points of leakage, thus decreasing venous hypertension and resulting complications; cost-effective; cosmetically acceptable (improving appearance while leaving few, if any, permanent areas of discoloration or scars); obviate the necessity for extended periods of unemployment or absence from usual daily activities. Foam sclerotherapy with SFJ ligation under local anaesthetic, as assessed in the short term meets all of the above criteria.

We have shown that there are significant early advantages with the new technique versus the conventional operation in the management of primary varicose veins. Long-term studies are needed to determine the ultimate fate of the residual GSV after foam sclerotherapy.

Acknowledgements

This study was supported by an unrestricted grant from STD Pharmaceuticals, Hereford, UK (DB).

This study received the Gunner-Bauer prize in the Baltic Venous Forum 2004.

References

- 1 MAC KENZIE RK, ALLAN PL, RUKLEY CV, BRADBURY AW. The effect of long saphenous vein stripping on deep venous reflux. *Eur J Vasc Endovasc Surg* 2004;**28**:104–107.
- 2 NEGLÉN P. Long saphenous vein stripping is favored in treating varicose veins. *Dermatol Surg* 2001;**27**:901–902.
- 3 RUDGERS PH, KIRSLAAR PJ. Randomised trial of stripping versus high ligation combined with sclerotherapy in the treatment of the incompetent greater saphenous vein. *Am J Surg* 1994;**168**:311–315.
- 4 ORBACH EJ. Contribution to the therapy of the varicose complex. *J Int Coll Surg* 1950;**13**:765–771.
- 5 FRULLINI A, CAVEZZI A. Sclerosing foam in the treatment of varicose veins and telangiectases: history and analysis of safety and complications. *Dermatol Surg* 2002;**28**:11–15.
- 6 HSU TS, WEISS RA. Foam sclerotherapy: a new era. *Arch Dermatol* 2003;**139**:494–496.
- 7 WOLLMANN JC. The history of sclerosing foams. *Dermatol Surg* 2004;**30**:694–703.
- 8 KISTNER RL, EKLOF B, MASUDA EM. Diagnosis of chronic venous disease of the lower extremities: the 'CEAP' classification. *Mayo Clin Proc* 1996;**71**:338–345.
- 9 MEISSNER MH. Venous duplex scanning. In: RUTHERFORD RD, ed. *Vascular surgery*. 5th ed Philadelphia: W.B. Saunders, 2000:214–229.
- 10 KISTNER RL, EKLOF B, MASUDA EM. Diagnosis of chronic venous disease of the lower extremities: the 'CEAP' classification. *Mayo Clin Proc* 1996;**71**:338–345.
- 11 NICOLAIDES AN, Members of the Executive Committee. Classification and grading of chronic venous disease in the lower limbs: a consensus statement. In: GLOVICZKI P, YAO JST, eds. *Handbook of venous disorders*. London: Chapman and Hall, 1996:652–660.
- 12 RUTHERFORD RB, PADBERG Jr FT, COMEROTA AJ, KISTNER RL, MEISSNER MH, MONETA GL. Venous severity scoring: an adjunct to venous outcome assessment. *J Vasc Surg* 2000;**31**:1307–1312.
- 13 CAVEZZI A, TESSARI L, FRULLINI A. A new sclerosing foam in the treatment of varicose veins: Tessari method. *Minerva Cardioangiol* 2000;**48**(Suppl 1):248.
- 14 JONES L, BRAITHWAITE BD, SELWYN D, COOKE S, EARNSHAW JJ. Neovascularisation is the principal cause of varicose vein recurrence: results of a randomised trial of stripping the long saphenous vein. *Eur J Vasc Endovasc Surg* 1996;**12**:442–445.
- 15 HOBBS JT. Surgery and sclerotherapy in the treatment of varicose veins. A random trial. *Arch Surg* 1974;**26**:793–796.
- 16 CABRERA J, CABRERA Jr J, GARCIA-OLMEDO MA. Treatment of varicose long saphenous veins with sclerosant in microfoam form: long-term outcomes. *Phlebology* 2000;**15**:19–23.

- 17 CAVEZZI A, FRULLINI A, RICCI S, TESSARI L. Treatment of varicose veins by foam sclerotherapy: two clinical series. *Phlebology* 2002; **17**:13–18.
- 18 KAHLE B, LENG K. Efficacy of sclerotherapy in varicose veins—prospective, blinded, placebo-controlled study. *Dermatol Surg* 2004;**30**:723–728.
- 19 SMITH JJ, GARRATT MG, GREENHALGH RM *et al.* Evaluating and improving health related quality of life in patients with varicose veins. *J Vasc Surg* 1999;**30**:710–719.
- 20 HAMEL-DESNOS C, DESNOS P, WOLLMANN JC, OUVRY P, MAKO S, ALLAERT FA. Evaluation of the efficacy of polidocanol in the form of foam compared with liquid form in sclerotherapy of the greater saphenous vein: initial results. *Dermatol Surg* 2003; **29**(12):1170–1175 [discussion 1175].
- 21 KOTOED SC, QVAMME GM, SCHROEDER TV, JAKOBSEN BH. Causes of need of reoperation following surgery for varicose veins in Denmark. *Ugeskr Laeger* 1999;**8**:779–783.
- 22 CORDER AP, SCHACHE DJ, FARQUHARSON SM, TRISTRAM S. Wound infection following high saphenous ligation. A trial comparing two skin closure techniques: subcuticular polyglycolic acid and interrupted monofilament nylon mattress sutures. *J R Coll Surg Edin* 1991;**28**:11–15.
- 23 KAKKOS SK, RIVERA MA, MATSAGAS MI, LAZARIDES MK, ROBLESS P, BELCARO G *et al.* Validation of the new venous severity scoring system in varicose vein surgery. *J Vasc Surg* 2003; **38**(2):224–228.

Accepted 7 August 2005